

Dynamic 3D MRI Of the whole Lung using Constrained Reconstruction with learned dictionaries

Sampada Bhawe¹, Sajan Goud Lingala², John Newell¹, Alejandro Comellas¹, and Mathews Jacob¹

¹University of Iowa, Iowa City, Iowa, United States, ²Electrical Engineering, University of Southern California, Los Angeles, California, United States

Targeted Audience: Clinicians and researchers interested in 3D dynamic lung MRI as a useful tool to assess global as well as regional lung function

Purpose: Since MR uses non-iodizing radiation, 3D dynamic MR imaging of respiratory mechanics is a promising alternative to CT. Abnormal function of the diaphragm and chest wall resulting from obesity and neuro-muscular disorders, clinically manifests as dyspnea. Spirometry measurements¹, which is one of the current standard diagnostic test, provides only global parameters such as lung volumes, airflow, and airway resistance. These are often non-specific to lung diseases and also are not sensitive to detect early lung function changes since they do not provide any spatial information. Current clinical lung protocols lack the temporal resolution and slice coverage required to image the dynamics of the entire thorax. In this work, we demonstrate a rapid imaging scheme for free breathing 3D dynamic lung MRI by using dictionary learning in combination with parallel imaging and radially sampled acquisitions. This scheme exploits the sparsity of the dynamic data in a dictionary of basis functions learned from the measured data. This scheme is similar to the traditional blind compressed sensing scheme², except that the basis functions are constrained to be sparse in the Fourier transform domain to exploit the pseudo-periodic respiratory and cardiac motion.

Methods: The data is modeled as a product of a sparse coefficient matrix $U_{M \times R}$ and the dictionary of temporal basis functions $V_{R \times N}$, where M , N and R are the number of pixels in the frame, number of time frames and the number of basis functions respectively. The reconstruction is posed as an optimization problem with the sparsity promoting l_1 -norm constraint on the coefficients U and on the Fourier transform of dictionary V :

$$\min_{\{U, V\}} \|A(UV) - b\|_2^2 + \lambda_1 \|U\|_1 + \lambda_2 \|R(V)\|_1;$$

where b is the under-sampled measured data and λ_1, λ_2 are the regularization parameters. Operator A considers the coil sensitivity encoding and the under-sampled Fourier transform on the radial trajectory. The operator R computes Fourier transform on V . The data was collected on a healthy volunteer on Siemens 3T Trio scanner with a body and spine array coil using a radial FLASH sequence with a 3D stack of stars trajectory³. The acquisition uses golden angle radial trajectory along (kx-ky) plane combined with a conventional 3D encoding step in the kx direction. The sequence parameters are: FOV= 350mm, TR/TE= 2.37ms/0.92ms. Base matrix size: 128x128, Resolution: 2.7x2.7x10mm³. A total of 3500 radial spokes were acquired in each partition and a total of 18 partitions were acquired to obtain whole lung coverage. The data was binned by considering 16 spokes per frame resulting in a total of 217 frames. The subject was asked to take a deep breath in and blow it completely throughout the scanning time. This breathing maneuver gave the measure of the total lung capacity at end inspiration and residual volume at end expiration. The temporal resolution of 680ms was achieved. The slice-by-slice reconstruction was performed using the proposed dictionary learning scheme. The results were compared to view sharing method, which is the standard technique for dynamic lung MRI reconstruction. Lung segmentation was performed using region-growing algorithm. The lung volume at each time point was measured as the total number of non-zero pixels in the masks obtained after lung segmentation at that time point.

Results and Discussion: The comparisons of proposed scheme with view sharing are shown in Fig. 1. We observe that proposed scheme gives superior reconstructions as compared to the view sharing. View sharing resulted in temporal blurring especially along the diaphragm borders and aliasing artifacts. Fig. 2 shows the change in lung volume as a function of time. This can be correlated with spirometry measurements. The images at full inspiration and full expiration are shown. The corresponding lung segmentation masks are also shown. Once the lung has been segmented a variety of physiological measures such as the velocity of the diaphragm and regional lung deformation can be estimated by the deformation maps obtained from lung registration. However, these parameters have not been thoroughly studied, as achieving high spatial and temporal resolution along with whole lung coverage is a big challenge in MRI. Future work includes systematically studying and obtaining different physiological measures from segmented lung data and analyzing the proposed scheme over multiple patient datasets.

Conclusion: In this work we present a dictionary learning based algorithm which accelerates 3D dynamic lung imaging with high temporal and spatial resolution as well as whole lung coverage.

References: [1] Gold. In, Textbook of Respiratory medicine 2000, [2] Lingala et. al, IEEE TMI 2013, [3] Chandrana et al, ISMRM'2012

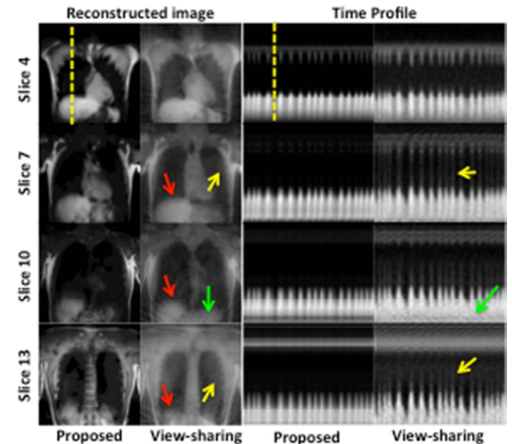


Figure 1: Comparison of proposed scheme against view sharing: We observe that proposed scheme yields better reconstruction than view sharing as seen in the images. View sharing exhibits temporal blurring along the diaphragm borders as shown by the red arrows and aliasing artifacts shown with yellow arrows. The green arrows correspond to the streaking artifacts

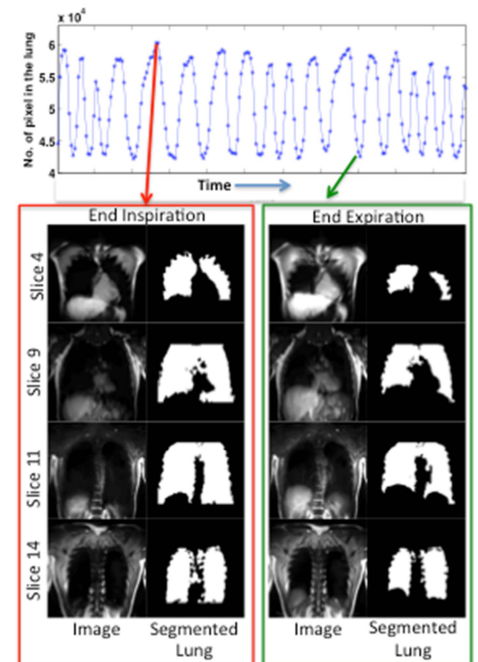


Figure 2: Change in lung volume: The plot shows change in lung volume as a function of time. Frame for a few slices along with their lung segmentation masks are shown for full inspiration and full expiration